

Radiation-induced Alopecia

Sir,

Radiotherapy is a common modality in cancer treatment and more than 50% of affected patients will eventually receive some form of radiotherapy as definite, preoperative, postoperative or palliative treatment.^[1]

Radiotherapy can result in certain inevitable side effects, radiation-induced cutaneous side effects that include acute and chronic radiodermatitis^[2] and systemic side effects.^[3] Skin may be injured as an 'innocent bystander' and develop profound alterations on functional, gross and molecular levels.^[4]

A 65-year-old man presented with a history of hair loss in the beard area while receiving radiotherapy for oropharyngeal carcinoma. Hair loss over the beard area was noted two weeks after the initiation of radiotherapy. There was no history of chemotherapy or surgery done for the tumor. Physical examination revealed 10×8 cm irregular patch of near total hair loss of the beard region [Figure 1]. The beard area was normal and exclamation-mark hairs were not visible; results of the pull test were normal. Excluding the diagnosis of alopecia areata may be difficult because the bald patch is devoid of inflammatory signs and hair loss is characterized by dystrophic hair.

It was not long before that the physiological effects of radiation were noticed. In April 1896, Daniel described epilation and a serious skin reaction after prolonged exposures; other reports soon followed, the realization that the large doses of X-rays produced harmful effects on the skin suggested that beneficial effects on skin diseases might be obtained with lower doses. In 1896, Freund of Vienna observed epilation by X-ray therapy of a large hairy nevus and followed this by treating various inflammatory diseases,

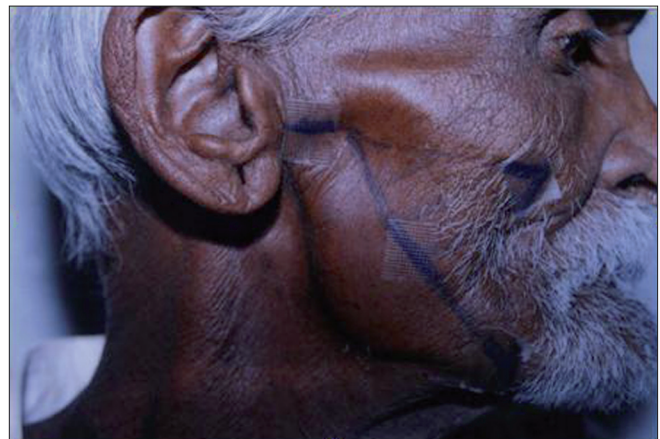

Figure 1: Radiation-induced alopecia


including eczema, psoriasis and ringworm, with X-rays.^[5]

Irradiation-induced epilation is due to high susceptibility of anagen follicles to radiation. Loss of dystrophic hairs (anagen effluvium) due to acute damage to actively dividing matrix cells of anagen follicles is followed by telogen shedding due to premature catagen entry of follicles in late anagen.^[6] 3GY produces complete, reversible anagen alopecia; permanent alopecia begins to occur at 5GY.^[7,8] Complete hair regrowth generally occurs 2–4 months after irradiation in reversible type of radiation-induced alopecia.^[6] Post-radiotherapy and permanent alopecia can be addressed by reconstructive surgery.^[9] Use of nitroxides tempol and tempo, vitamin D3 and 16, 16-dimethyl prostaglandin E2 (PGE2) prior to radiation have been shown to protect against radiation-induced alopecia.^[10–12]

The present case is being reported for the awareness of the radiation-induced alopecia as radiotherapy is the commonly used modality for the treatment of head and neck carcinomas.

Syed Yousuf Ali, Gurcharan Singh¹

Department of Dermatology and STD,
Shadan Institute of Medical Sciences, Peerancheru,
Hyderabad, Andhra Pradesh,

Access this article online	
Website: www.ijtrichology.com	Quick Response Code 
DOI: 10.4103/0974-7753.77528	

Letters to Editor

¹Sri Devaraj Urs Medical College, Kolar, Karnataka, India

Address for correspondence:

Dr. Syed Yousuf Ali

H. No: 9-4-77/A/79, Al Hasnath Colony, Toli Chowki,
Hyderabad-500 008, Andhra Pradesh, India.

E-mail: syedbidar@gmail.com

REFERENCES

1. Omidvari S, Saboori H, Mohammadianpanah M, Mosalaei A, Ahmadloo N, Mosleh-Shirazi MA, *et al.* Topical betamethasone for prevention of radiation dermatitis. *Indian J Dermatol Venereol Leprol* 2007;73:209-15.
2. Venkatesan S, Thappa DM, D'Souza M, Ratnakar C. Radiation induced localized bullous pemphigoid. *Indian J Dermatol* 1998;43:182-4.
3. Lichter SA. Radiation therapy. In: Abeloff MD, Armitage JO, Lichter AS, Niederherber JE, eds. *Clinical oncology*. 2nd ed. New York: Churchill Livingstone Publisher; 2000. p. 423-70.
4. Hymes SD, Strom EA, Fife C. Radiation dermatitis: Clinical presentation, path physiology and treatment 2006. *J Am Acad Dermatol* 2006;54: 28-46.
5. Cipollero AC, Crossland PM. X rays and radium in the treatment of diseases of the skin, 5thed. Philadelphia: Lea and Febiger Publishers; 1967.
6. Wen CS, Lin SM, Chen JC, Wang YH, Tseng SH. Radiation-induced temporary alopecia after embolization of cerebral arteriovenous malformations. *Clin Neurosurg* 2003;105:215-7.
7. Malkinson FD, Panizzon RG. Radiobiology and radiotherapy of skin diseases. In: Freedberg IM, Eisen AZ, Wolff K, Austen KF, Goldsmith LA, Katz SI, editors. *Fitzpatrick's dermatology in general medicine*, 6th ed. New York: McGraw Hill Medical Publishing Division, 2003. p. 1229-38.
8. Severs GA, Griffin T, Werner-Wasik M. Cicatricial alopecia secondary to radiation therapy: Case report and review of the literature. *Cutis* 2008;81:147-53.
9. Rannan-Eliya YF, Rannan-Eliya S, Graham K, Pizer B, McDowell HP. Surgical interventions for the treatment of radiation-induced alopecia in pediatric practice. *Pediatric Blood Cancer* 2007;49:731-6.
10. Cuscela D, Coffin D, Lupton GP, Cook JA, Krishna MC, Bonner RF, *et al.* Protection from radiation-induced alopecia with topical application of nitroxides: Fractionated studies. *Cancer I Sci Am* 1996;2:273-8.
11. Baltalarli B, Bir F, Demirkan N, Abban G. The preventive effect of vitamin D3 on radiation-induced hair toxicity in a rat model. *Life Sci* 2006;78: 1646-51.
12. Hanson WR, Pelka AE, Nelson AK, Malkinson FD. Subcutaneous or topical administration of 16, 16 dimethyl prostaglandin E2 protects from radiation-induced alopecia in mice. *Int J Radiat Oncol Biol Phys* 1992;23:333-7.